



MAHATMA GANDHI DENTAL COLLEGE & HOSPITAL, JAIPUR

(MAHATMA GANDHI UNIVERSITY OF MEDICAL SCIENCES AND TECHNOLOGY, JAIPUR – NAAC A+ Accredited)

No. MGDCH/CDE/DCR/2025/08

Date: 05/05/2025

33rd DENTAL COMBINED ROUND (DCR)

on

"Complete Oral Rehabilitation and Space Management in a 6½-Year-Old Child"

by

Department of Pedodontics with Preventive Dentistry

Speakers

Dr. Mrunal Bandivar

PG Resident (III)

Dept. of Pedodontics with preventive dentistry

Dr. Muskan Rathore

PG Resident (II)

Dept. of Pedodontics with preventive dentistry

Under the Guidance of

Dr. Anant G Nigam

Prof. and Head

Dept. of Pedodontics with preventive dentistry

Moderator

Dr. Reema Sharma

Reader

Dept. of Pedodontics with preventive dentistry

Dr. Anant Gopal Nigam
PG Resident (III)
Dept. of Pedodontics with preventive dentistry
MGDCH - JAIPUR

Chairperson

Dr. M. L. Swarankar

Emeritus Chairperson

MGUMST

Wednesday, May 7th 2025, at 02.00pm-03.00pm Venue:

LT-1, MGDCH

All HODs, Faculty members and Residents of Mahatma Gandhi Dental College and Hospital, Jaipur must attend the DCR in LT-1 at 2.00 pm sharp. The 34th DCR will be conducted on 21st May, 2025 by Dept. of Orthodontics & Dentofacial Orthopedics.

Dr. Achal Gulati
President cum Vice Chancellor
MGUMST

Dr. V. K. Kapoor
Pro. Vice Chancellor
MGUMST

Dr. Narendra Padiyar U.
Principal & Dean
MGDCH

Dr. Anshuman Jamdade
Professor and Head
Dept of Oral Medicine & Radiology,
Convenor, DCR

Copy to-

1. PS to the Chairperson, MGUMST
2. PS to the President, MGUMST
3. PS to the Pro-President, MGUMST
4. Principal & Controller, MGMC&H
5. Principal & Controller, MGDC&H
6. Principal Adviser to Chairperson, MGUMST
7. Director, Hospital Administration, M.G.H.
8. Medical Superintendent, MGH
9. Heads of the Departments-M.G. Dental College
10. Director, IOAC, MGUMST
11. Co-Ordinator, IQAC, MGDCH
12. I/c Media Centre
13. Office copy

DCR EVENT REPORT

Date: 05/05/2025

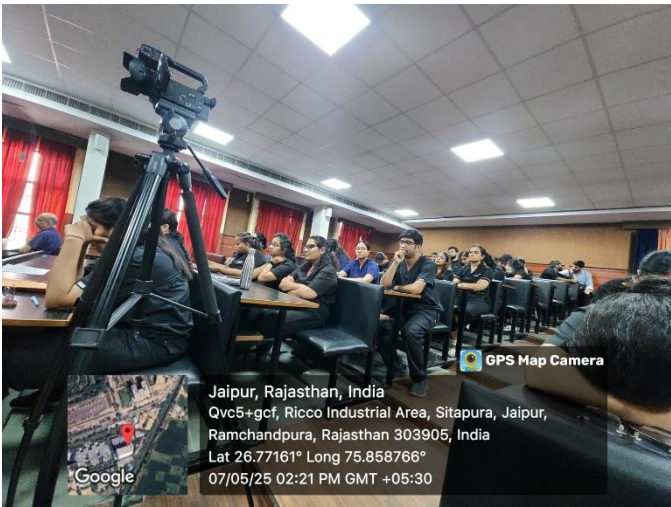S.No.	Event report
1	Name & level of Event- “33 rd Dental Combined Round (DCR)”
2	Background/Introduction- Topic of Program- “Complete Oral Rehabilitation and Space Management in a 6 ½ year old child” Date- 07-05-2025 Name of Organizing Committee- Department of Pediatric & Preventive Dentistry Programs Organized- DCR Time of Commencing Program- 2:00 PM IST Time of Conclusion: 3:00 PM IST Total Attendees- 70
3	Venue- LT-1, Mahatma Gandhi dental College & Hospital
4	Sponsors- MGUMST
5	Inauguration- Performed by Dr. Narendra Padiyar
6	Speakers/Judges/Chairman/Panel team- Speakers- Dr. Mrunal Bandiwar, Dr. Muskan rathore Moderator- Dr. Reema Sharma
7	Participants & Delegates- All HODs, Faculty Members and residents of Mahatma Gandhi Dental College & Hospital
8	Prize Distributions, etc- Certificates awarded to all the speakers
9	Valedictory Ceremony- nil
10	Highlights of the event- nil
11	Geo-Tagged Photographs- Attached

Dr. Narendra Padiyar
Dean, MGDCH



Dr. Narendra Padiyar
Dean, MGDCH

Program Coordinator
IQAC



Dr. Anant Gopal Nigam
Head, Physical & Occupational Therapy
Jaipur Engineering College & Hospital
Jaipur - A-54005

Department of Pediatric and Preventive Dentistry

Complete Oral Rehabilitation and Space Management in a Child 6 ¹/₂ Years of Age

Speakers:

Dr. Muskan Bhandwar
Resident (III)
Dept. of Pediatric and
Preventive Dentistry

Dr. Muskan Bhandwar
Resident (II)
Dept. of Pediatric and
Preventive Dentistry

Moderator:

Dr. Roopa Sharma
Reader
Dept. of Pediatric and Preventive Dentistry

Guided by:

Dr. Anant Gopal Nigam
Professor and Head,
Dept. of Pediatric and Preventive Dentistry

Case Report

General Information :

- Name : Advik Jain
- Age : 6 ¹/₂ yr
- Gender: Male
- Address: Kota
- Year: 2025



Chief Complaint:

A 6 ¹/₂ year old boy reported to the Department of Pediatric and Preventive Dentistry, MGDCH with the complain of multiple carious teeth in the upper and lower jaw since 2 years.

HISTORY OF PRESENT ILLNESS

- According to the parent, the child developed blackish discoloration on the upper and lower left back teeth, which has gradually increased in size over time.
- Recurrent history of pain on chewing in the upper and lower left back tooth region and upper right back tooth region.
- No swelling or pus discharge.
- No sensitivity to hot, cold or sweet foods.
- No bleeding from gums along with a positive history of food lodgment in the affected area.

Extra Oral Examination:

- **Shape of the Head:** Mesocephalic
- **Facial Form:** Mesoprosopic
- **Facial Profile:** Straight
- **Facial Swelling and Asymmetry:** No Abnormality Detected
- **Eyes:** No Abnormality Detected
- **Nose:** No Abnormality Detected
- **Skin:** No Abnormality Detected
- **Lips:** No Abnormality Detected
- **Chin:** No Abnormality Detected
- **TMJ:** No Abnormality Detected
- **Lymph Nodes:** Non-palpable

Intra Oral Examination:

- **Soft Tissue Examination:**
 1. Buccal Mucosa:
 - a) Colour- Pink
 - b) Texture- Smooth
 - c) Moist or Dry- Moist
 2. Tongue:
 - a) Colour- Pink
 - b) Papilla- Normal
 - c) Size- Normal
 - d) Shape- No Abnormality Detected
 3. Floor Of Mouth: No Abnormality Detected

- **Hard palate-** No Abnormality Detected

Patient reported for the treatment after 3 months, upon which following were the findings.

Hard tissue examination-

Grossly decayed- 51,52,54,61,62,64.
Mobility- 51,52,61,62,71,81,72,82 (Pre exfoliation mobility)
Smooth surface caries- 53,63
Occlusal caries- 85, 55,65,74,84
Proximal Caries - 75
Attrition -81,82,83,71,72,73

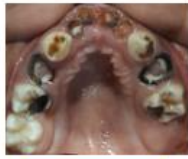4. Gingiva: No Abnormality Detected
5. Soft Palate: No Abnormality Detected
6. Tonsils: No Abnormality Detected
7. Adenoids: No Abnormality Detected

Hard Tissue Examination:

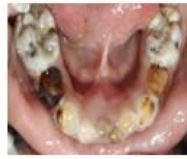- **Teeth present-** 55,54,53,52,51,61,62,63,64,65,71,72,73,74,75,81,82,83,84,85
- **Caries-**
 - ☐ Grossly decayed- 54,51,52,61,62,64
 - ☐ Smooth surface caries - 53,63
 - ☐ Proximal caries- 75
 - ☐ Occlusal caries - 85,55,65,74,84
 - ☐ Attrition - 73,72,71,81,82,83
- **Mobility-** Absent

Dr. Anant Gopal Nigam
Pediatric, Preventive & Prosthetic Dentistry
M.D.C.H. Govt Dental College & Hospital, Jaipur
RDC - A-5485

Pre Operative Photographs



Maxilla



Mandible



44

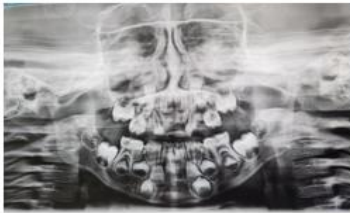Investigations

- Orthopantomogram (OPG)



45

Orthopantomogram (OPG)



46

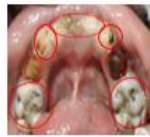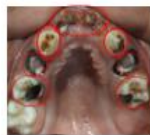Management



47

Treatment Plan

- ❑ Composite restoration- 53,63,73,83,74,84
- ❑ Pulpotomy- 85 followed by SSC
- ❑ Pulpectomy- 75,65,55 followed by SSC
- ❑ Extraction- 51,52,61,62,81,82,71,72
- ❑ Extraction followed by space maintainer - 54,64

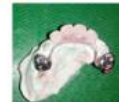

48

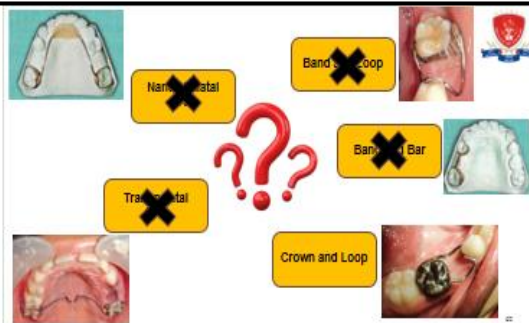
Removable
Partial Denture



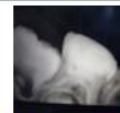
Gropers
Appliance



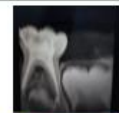49



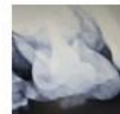50



Pulpotomy irt 85



Pulpotomy irt 75



Pulpotomy irt 55

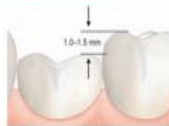
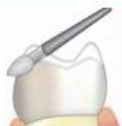
Pulpotomy irt 65



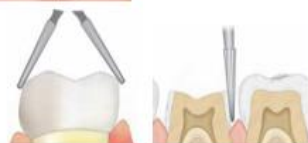51

Steps in Crown Preparation

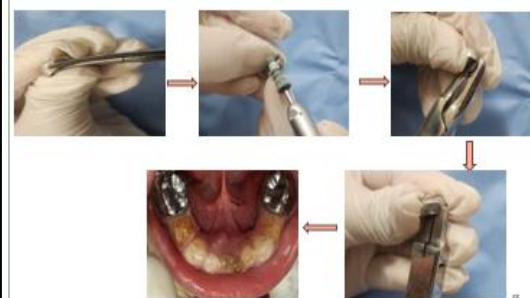

Occlusal Reduction

Proximal Reduction

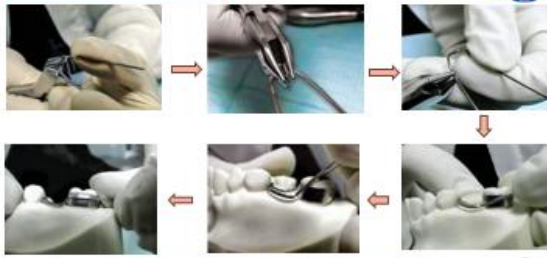

52

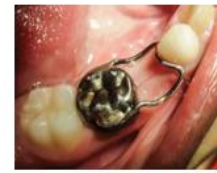

53

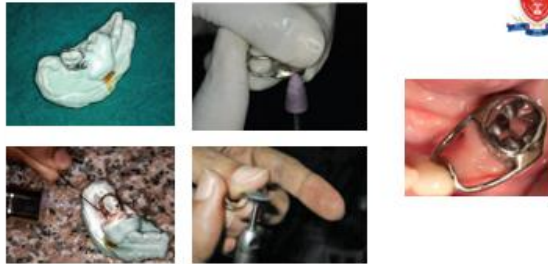
Fabrication of Loop



24

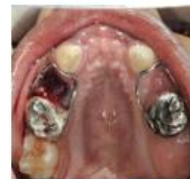

25

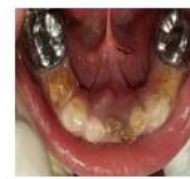

26

Post Operative Photographs

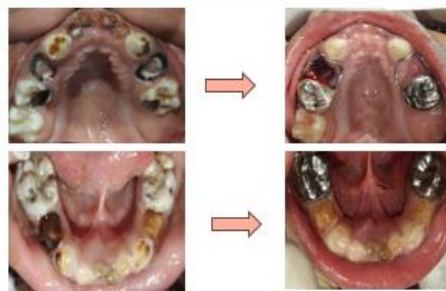

Maxilla



Mandible

27



28

Maintenance

1. Diet counselling.
2. Recall visits.
3. Application of Pit and Fissure sealants.
4. Proper brushing technique.
5. Use of fluoridated toothpaste.

29

Discussion

- **Cor fur Space Maintainers:** According to **Boucher** it is a fixed or removable appliance designed to preserve the mesio-distal space created by the premature loss of a primary tooth or a group of teeth.
- **Ina sev Space Maintenance:** This term was coined by **JC Brauer** in 1941. It is defined as the process of maintaining a space in a given arch previously occupied by a tooth or a group of teeth.
- The premature loss of primary teeth may cause loss of arch length, resulting in crowding of the permanent dentition, impaction of permanent teeth, esthetic difficulties, malocclusion, and other problems.

30

Indications-

- When there are Signs of closing of space after the premature loss of deciduous teeth.
- If the eruption of permanent tooth will take 2 years or longer
- To avoid supra eruption from opposite arch

Contraindications-

- If the radiograph shows that the Succedaneous tooth will erupt soon.
- One third of the root of succedaneous tooth is already formed.
- Succedaneous tooth is absent.

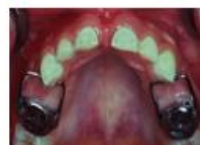31

Band and Loop space maintainer

It is a unilateral, nonfunctional, passive, fixed appliance indicated for space maintenance in the posterior segments when single tooth is lost.

Modifications

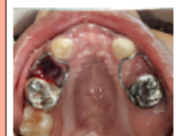1. Robert Rapp and Isak Demireo (1983)
2. Crown and loop
3. Crown-band and loop
4. Meyne's space maintainer
5. Reverse band and loop
6. Band and bar. Prevents eruption of premolar
7. Bonded band and loop
8. Long band and loop



32

Crown and Loop Space Maintainer

- SSC is used instead of band on the base tooth.
- Crown on the second primary molar with a soldered wire-loop extension extending forward to come into contact with the distal-cervical surface of the primary canine in the quadrant.
- 0.036- or 0.040-inch stainless steel wire
- Wire design approximates the gingival contour of the extraction space to avoid occlusal interference and is wide enough to allow the permanent tooth to erupt.



33

Advantages -

- Durability
- Dual function
- Prevents tooth drift
- improved retention
- Long term use

Disadvantages -

- Cost
- Technique sensitive
- Esthetics



24

ORIGINAL RESEARCH ARTICLE

Clinical success and longevity of band and loop compared to crown and loop space maintainers

M. A. Qudus¹, I. A. Ishaq²

A majority (83 %) of BAL space maintainers failed during the follow-up period. In comparison, failure rate for C&L space maintainers was 22 %. The rates for all space maintainers in this study are presented in Table 2. The main reason for failure of BAL space maintainers was decementation of the band (87 %), while for the C&L space maintainer, it was solder breakage (75 %).

Qudus M, Ishaq A. (2022) Clinical success and longevity of band and loop compared to crown and loop space maintainers. *European Archives of Paediatric Dentistry*, 18(2), 18-28.



25

Take Home Message

- Comprehensive caries management in pediatric dentistry combines "early detection, early intervention, and proactive space management" to ensure optimal oral health and proper dental development.
- Primary teeth play a key role in maintaining arch length, guiding the eruption of permanent teeth, supporting normal function and act as the best space maintainer.
- The use of space maintainers prevent drifting of adjacent teeth, loss of arch length, midline shifts and potential malocclusion. It helps maintain the integrity of the dental arch supports the proper eruption sequence of permanent teeth and reduces the need for complex orthodontic treatments later.



26

Acknowledgements

- Dr. M. L. Swarnkar Sir (Emeritus Chairperson MGUMST)
- Dr. Achal Gulati (President and Vice Chancellor)
- Dr. V. K. Kapoor (Pro-Vice Chancellor)
- Dr. Sudhir Sachdeva (Chief Advisor)
- Dr. Narendra Padiyar U. (Principal & Dean)
- Dr. Deepak Raisinghani (Additional Principal)
- Dr. Anshuman Jamdade (Head of Review Committee, DCR)
- Respected Heads of the Departments, Faculty members and Post graduate students
- We would also like to acknowledge the patient and his parents and guardian who were very cooperative and patient through-out the procedure and the follow-up visits.



27

Thank You!



28


Dr. Anant Copal Nigam
Professor, Pediatric & Preventive Dentistry
A Dental Institute, College & Hospital, Jaipur
RISDC - A-2665



Mahatma Gandhi Dental College & Hospital

MAHATMA GANDHI UNIVERSITY OF MEDICAL SCIENCES & TECHNOLOGY, JAIPUR
(Sponsoring Body : India Education Trust)

RIICO Institutional Area, Sitapura, Tonk Road, JAIPUR - 302 022 (Raj.) INDIA
Phone : 0141-2770300, 3292139 • Fax : 0141-2770326
email : principal.dental@mgumst.org

Date:

07/05/2025

33rd DENTAL COMBINED ROUND (DCR)
on

**“Complete oral rehabilitation and space management in a
child 6 ½ years of age.”**

Presenting Dept.: Department of Pedodontics with preventive dentistry

Staff Attendance Sheet

S.NO.	NAME	DESIGNATION	SIGNATURE
1.			
2.			
3.	Dr Narendra Padiyar U	Principal and Dean, Professor and Head, Dept of Prosthodontics and Crown and Bridge	
4.	Dr Deepak Raisingani	Professor and Head, Dept of Conservative Dentistry & Endodontics	
5.	Dr Sumanth Prasad	Professor and Head, Department of Public Health Dentistry	
6.	Dr Anshuman Jamdade	Professor and Head, Department Oral medicine and Radiology	
7.	Dr Anant Nigam	Professor and Head, Department of Pediatric & Preventive dentistry	
8.	Dr Kamal Bajaj	Professor and Head, Department of Orthodontics & Dentofacial Orthopedics	

Dr. Anant Nigam
Principal, Mahatma Gandhi Dental College & Hospital, Jaipur
Raj. - 302 022

	Dr Ashish Yadav	Professor and Head, Department of periodontology	Ashish
10.	Dr Vikas K. Singh	Professor and Head, Department Oral & maxillofacial surgery	Vikas
11.	Dr Manish Jain	Professor and Head, Department of Oral Pathology & Microbiology	
12.	Dr Shilpa Givveraj	Reader Oral Path	Shilpa
13.	Dr. Mukul Mathur	Sr. Lecturer (Oral Path)	Mukul
14.	Dr. Nivedita Saxena	Sr. Lecturer [Pedodontics]	N
15.	Dr. Chetan Choudhary	Reader Cons Endo	Chetan
16.	Dr Nivedita Jain	Sr. Lecturer (Cons & Endo)	Nivedita
17.	Dr. Aksha	Sr. Lecturer (OMFS)	Aksha
18.	Dr Reema Sharma	Reader Pedo	Reema
19.			
20.			
21.			
22.			
23.			
24.			
25.			
26.			
27.			
28.			
29.			
30.			
31.			
32.			

Dr. Ashish Gopal Nigam
 Director, Postgraduate & Research Institute
 All India Institute of Medical Sciences
 New Delhi - 110029



Mahatma Gandhi Dental College & Hospital

MAHATMA GANDHI UNIVERSITY OF MEDICAL SCIENCES & TECHNOLOGY, JAIPUR

(Sponsoring Body : India Education Trust)

RIIICO Institutional Area, Sitapura, Tonk Road, JAIPUR - 302 022 (Raj.) INDIA

Phone : 0141-2770300, 3292139 • Fax : 0141-2770326

email : principal.dental@mgumst.org

Date: 07/05/2025

33rd DENTAL COMBINED ROUND (DCR)
on

**“Complete oral rehabilitation and space management in a child
6 ½ years of age.”**

Presenting Dept.: Department of Pedodontics with preventive dentistry

Post-Graduate Attendance Sheet

S.NO.	DEPARTMENT	S.NO.	NAME OF POST-GRADUATE	SIGNATURE
1.	Oral Medicine And Radiology	1	Kanishka Singh	
		2	Monika Gupta	Monika
		3	Saurabh Kanawa	Saurabh
		4	Reeya Garg	Reeya
2	Oral And Maxillofacial Surgery	5	Aayushi Agarwal	Aayushi
		6	Krati Jajani	Krati
		7	Mahima Jain	Mahima
		8	Chokshi Krupa	Chokshi
		9	Tara Chand	Tara
		10	Pooja Sharma	Pooja
		11	Samiksha Pamnani	Samiksha
		12	Pooja Meena	Pooja
		13	Divesh Jain	Dy
		14	Avni Singh	Avni
		15	Hetal Vaya	Hetal
		16	Kshitij Kumawat	Kshitij
		17	Sanjeevani	Sanjeevani
		18	Shalu Choudhary	

[Signature]
The Assistant Professor
Pedodontics & Preventive Dentistry
Mahatma Gandhi Dental College & Hospital, Jaipur
BSC - A 945

		19	Swati Verma	
3	Prosthodontics And Crown & Bridge	20	Rajbir Kaur	Rajbir Kaur
		21	Naman Goyal	Naman
		22	Poonjee Gupta	
		23	Ayushi Goyal	Ayushi
		24	Khandhedia Harsh Jayeshkumar	
		25	Rishika Singh	Rishika
		26	Sanya Dayma	
		27	Patil Shweta Narendra Kumar	Shweta
		28	Khushboo Meena	Khushboo
		29	Sheetal Vijay	
		30	Akanksha Verma	
		31	Muskan Malik	
		32	Nandini Sharma	
		33	Prachi Singh	Prachi
		34	Shruti Ashok Rathod	
4	Conservative Dentistry & Endodontics	35	Sohan Sharma L	Sohan
		36	Chanchal Meena	Chanchal
		37	Ruchi Chandak	
		38	Poorva Sharma	Poorva
		39	Anshum Jain	Anshum
		40	Kusum Meena	Kusum
		41	Praveen Singh Chauhan	
		42	Sakshi Bilaiya	
		43	Vookanti Venkat Ramana Reddy	
		44	Mohit Kumar Jyotiyana	
		45	Anusha Saxena	Anusha
		46	Khushi Bhargava	
		47	Kiran Gurdasani	Kiran
		48	Saumya Kanode	Saumya
		49	Mutyalarwar Sunaina Shanka	Sunaina

			Shankar	
5	Paediatrics & Preventive Dentistry	50	Vipul Sharma	<i>Vipul</i>
		51	Simran Vangani	<i>Simran</i>
		52	Vritika Singh	<i>Vritika</i>
		53	Ghawate Nikhil Dattatraya	<i>Nikhil</i>
		54	Mrunal Milind Bandiwar	
		55	Harsha Patni	
		56	Riya Bafna	<i>Riya</i>
		57	Surbhi Surana	<i>Surbhi Surana</i>
		58	Anugya Jain	<i>Anugya</i>
		59	Muskan Rathore	
		60	Sanjana Verma	
		61	Sanika Pravin Rathi	
		62	Khushboo Parihar	
		63	Sanchi Pramod Meshram	
		64	Aditi Choudhary	
6	Periodontology	65	Hemant Sharma	<i>Hemant</i>
		66	Shashidhar Ojha	<i>Shashidhar</i>
		67	Vaishali Sharma	
		68	Pooja Shukla	
		69	Srashti Katiyar	<i>Srashti</i>
		70	Priyanka Pawar	<i>Priyanka</i>
		71	Aakanksha	
		72	Abhivyakti Rajput	<i>Abhivyakti</i>
		73	Keertika Rathore	
7	Orthodontics & Dentofacial Orthopaedics	74	Priyanka Agarwal	<i>Priyanka</i>
		75	Mausham Chaudhary	<i>Mausham</i>
		76	Harshita Gautam	<i>Harshita</i>
		77	Soni Hitesh Kumar	
		78	Pallavi Goswami	<i>Pallavi</i>
		79	Modak Ankur Rahul	<i>Modak</i>
		80	Heena Khan	<i>Heena</i>
		81	Richa Sharma	<i>Richa</i>

		82	Mantrishna Sarma	Mantrishna
		83	Nivita Jewaria	Nivita
		84	Adarsh	Adarsh
		85	Divyansh Raghav	
		86	Pooja Sharma	Pooja
		87	Rashmi Upadhyay	Rashmi
		88	Sanya Mathur	Sanya


 Anant Gopal Nigam
 Director, Education & Professional Training
 Government of India, New Delhi-110002
 MOBILE: 98100 12345

