



Mahatma Gandhi Dental College & Hospital

MAHATMA GANDHI UNIVERSITY OF MEDICAL SCIENCES & TECHNOLOGY, JAIPUR

(Sponsoring Body : India Education Trust)

RIICO Institutional Area, Sitapura, Tonk Road, JAIPUR - 302 022 (Raj.) INDIA

Phone : 0141-2770300, 3292139 • Fax : 0141-2770326

email : principal.dental@mgumst.org

No. MGDCH/CDE/DCR/2025/01

Date:03/01/2025

26th DENTAL COMBINED ROUND (DCR)

on

“A comprehensive full mouth rehabilitation in a 20-month-old child under general anesthesia”

Department of Pediatrics & Preventive Dentistry

Speakers

Dr. Nikhil Ghawate

PG Resident (III MDS)

Department of Pediatrics & Preventive Dentistry

Dr. Anugya Jain

PG Resident (II MDS)

Department of Pediatrics & Preventive Dentistry

Under Guidance of

Dr. Anant G. Nigam

Prof. and Head

Department of Pediatrics & Preventive Dentistry

Dr. Shantanu Jain

Professor

Department of Pediatrics & Preventive Dentistry

Moderator

Dr. Shantanu Jain

Professor

Department of Pediatrics & Preventive Dentistry

Chairperson

Dr. M. L. Swarankar

Emeritus Chairperson

MGUMST

Wednesday, January 08, 2025, at 02.00pm-03.00pm

Venue:LT-1, MGDCH

All HODs, Faculty members and Residents of Mahatma Gandhi Dental College and Hospital, Jaipur must attend the DCR in LT-1 at 2.00pm sharp. 27th DCR will be conducted on 22nd January, 2025 by Dept. of Oral Medicine & Radiology.

Dr. Achal Gulati

President cum Vice Chancellor
MGUMST

Dr. V. K. Kapoor

Pro. Vice Chancellor
MGUMST

Dr. Narendra Padiyar U.

Principal & Dean
MGDCH

Dr. Anshuman Jamdade

Professor and Head
Dept of Oral Medicine & Radiology,
Convenor, DCR

Copy to-


1. PS to the Chairperson, MGUMST
2. PS to the President, MGUMST
3. PS to the Pro-President, MGUMST
4. Principal & Controller, MGMC&H
5. Principal & Controller, MGDC&H
6. Principal Adviser to Chairperson, MGUMST
7. Medical Superintendent, MGH
8. Heads of the Departments-Medical College
9. Heads of the Departments-Dental College
10. Director, IOAC, MGUMST
11. Co-Ordinator, IQAC, MGDCH
12. Mr. Virendra Pareek, Director (Marketing) & PRO
13. Mr. Pradeep Das, Incharge Auditorium
14. Office copy

(Signature)
Dr. Anant Gopal Nigam
Principal & Dean
Mahatma Gandhi Dental College & Hospital
Jaipur - 302 022

DCR Event Report


Date: 03/01/2025

| S.No. | Event Report |
|-------|---|
| 1. | Name & Level of Event- "26th Dental Combined Round (DCR)" |
| 2. | Background/ Introduction- Topic of Program: "A comprehensive full mouth rehabilitation in a 20-month-old child under general anesthesia" Date: 08/01/2025 Name of the Organizing Committee: Department of Pediatric and Preventive Dentistry Programs Organised: DCR Time of commencing program: 02:00 pm IST Time of Conclusion: 03:00 pm IST Total attendees: 76 |
| 3. | Venue: LT-1, Mahatma Gandhi Dental College and Hospital |
| 4. | Sponsors: MGUMST |
| 5. | Inauguration: Performed by Dr. Narendra Padiyar |
| 6. | Speaker/Judges/Chairman/Panel Team: Speakers: Dr. Nikhil Ghawte, Dr. Anugya Jain. Moderator: Dr. Shantanu Jain |
| 7. | Participants & Delegates: All HODs, Faculty members and Residents of Mahatma Gandhi Dental College and Hospital |
| 8. | Prize Distribution etc.: Certificates awarded to all Speakers |
| 9. | Valedictory Ceremony: nil |
| 10. | Highlights of the Event: nil |
| 11. | Geo-tagged Photograph: Attached |


Dr. Narendra Padiyar

Dean, MGDCH
Principal

**Mahatma Gandhi Dental College &
Hospital, Sitapura, Jaipur-302022**


Program coordinator

Dr. Anant Gopal Nigam
Prin. & Head, Pediatric & Preventive Dentistry
Mahatma Gandhi Dental College & Hospital, Jaipur
RSDC - A-5405




 Apant Gopal Nigam
 Director, Planning & Financial Control
 Rajiv Gandhi National Science & Innovation, Jaipur
 RGSIIC - A-5485

DENTAL CLINICAL COMBINED ROUNDS

DEPARTMENT OF PEDIATRIC & PREVENTIVE DENTISTRY

PRESENTED BY :

Dr. Nikhil Ghawate
PG- III Year
Department of Pediatric & Preventive
Dentistry

Dr. Anugya Jain
PG- II Year
Department of Pediatric & Preventive
Dentistry

GUIDED BY:

Dr. Anant Gopal Nigam
Professor And HOD
Department of Pediatric & Preventive Dentistry

MODERATED BY:

Dr. Shantanu Jain
Professor
Department of Pediatric & Preventive Dentistry

COMPREHENSIVE FULL MOUTH REHABILITATION OF A 20 MONTHS OLD CHILD UNDER GENERAL ANAESTHESIA

CASE REPORT

- **AGE/SEX** – 20 months / male child
- **CHIEF COMPLAINT**- Child's parents c/o discomfort & swelling in upper front tooth region for past 15 days.
- **HOP** - The child had a history of discomfort and swelling in upper front tooth region for past 15 days. The parents reported history of difficulty in eating and the child was not given any medications for the same.

PERSONAL HISTORY-

1. History of breastfeeding till 18 months.
2. Poor oral hygiene.
3. No history of maintenance of oral hygiene by parents
4. No habit of bottle feeding

- **PRE NATAL HISTORY**- Mother was not on any medication during pregnancy
- **NATAL HISTORY**- Child was delivered normally without any C-Section or forcep delivery
- **POST NATAL HISTORY**- Child did not have any complication after birth
- **PAST MEDICAL HISTORY**- No history of previous hospitalisation
- **PAST DENTAL HISTORY**- First dental visit

ORAL EXAMINATION-

➤ EXTRAORAL –

Swelling in upper front left region extending from ala of the nose till philtrum of the mouth.

➤ INTRAORAL –

1. Swelling in upper front tooth region in labial fold irt 61
2. Deep Dentinal Caries irt 54, 52, 51, 61, 62
3. Grade II mobility irt 61

ORAL EXAMINATION DONE IN MOTHER'S LAP



Anant Gopal Nigam
Professor And HOD
Department of Pediatric & Preventive Dentistry
Dental College & Hospital, Jaipur
RSCMC - A-540

DEVELOPMENTAL MILESTONES OF A 2-YEAR-OLD CHILD

| EMOTIONAL | MENTAL | MOTOR |
|---|---|--|
| <ul style="list-style-type: none"> Self-centered Cannot share Gives up readily Clings to familiar people Easily distracted Easily frustrated Complete dependence on adults | <ul style="list-style-type: none"> Investigative—touch, taste One thing at a time Cannot recognize Attention span 1–5 min Irresponsible Concepts of family only Needs own name used Matches words with objects One/two word sentences Wide vocabulary range 5–200 words | <ul style="list-style-type: none"> Unsteady Wide stance, body forward Depends on adult for dressing Hugs, topples Whole body action Climbs onto stairs Push-pull, pokes Awkward with small objects |

PRE-OPERATIVE PHOTOGRAPHS

1. Deep Dental Caries in 52,51,61,62 (Palatal view)

2. Deep Dental Caries in 52,51,61,62 (Labial view)

3. Deep Dental Caries in 54

DIFFERENTIAL DIAGNOSIS

DIFFERENTIAL DIAGNOSIS

RAMPANT CARIES

- It occurs in **all age group** including adolescence associated with **immunological factors**.
- It occurs in both **primary and permanent dentition**
- Mandibular incisors** are usually affected
- Multifactorial **etiology** like frequent snacking excessive sticky refined carbohydrate intake, decrease salivary flow and genetic background.

NURSING BOTTLE CARIES

- Specific form of rampant caries
- It occurs in **infants, toddler or preschoolers**
- Affect the **primary dentition** only
- Mandibular incisors are not affected**
- Primarily associated to improper feeding practice such as **bottle feeding** or pacifier feeding during sleep.

EARLY CHILDHOOD CARIES

- Presence of one or more decayed, missing (as a result of caries), or filled tooth surfaces in any primary tooth in a child **71 months of age or younger**. (AAPD, 2024)
- Any sign of dental caries on any tooth surface **during the first 3 years of life**.
- Affects the **maxillary primary incisors and first primary molars**. In severe cases, **mandibular incisors and molars** are also involved.

American Academy of Pediatric Dentistry. Policy on early childhood caries (ECC): Consequences and preventive strategies. The Reference Manual of Pediatric Dentistry. AAPD Manual; 2024:89-92.

Adarsh Gopal Nigam
 MSc, BDS, FRCR, FRCR (Dent), FRCR (Dent), FRCR (Dent), FRCR (Dent)
 Consultant in Paediatric Dentistry, Jawahar Institute of Postgraduate Medical Education & Research, Pondicherry
 822002 - A-5405

DIAGNOSIS

**EARLY CHILDHOOD CARIES irt
54, 52, 51, 61, 62**

17

TREATMENT PLAN

- Extraction irt 61
- Pulpectomy irt 52, 51, 62
- Restoration irt 54
- General Anaesthesia was opted for performing the treatment as the child was "DEFINITELY NEGATIVE" (Acc. To Frankl Behaviour Rating Scale).

18

FRANKL BEHAVIOUR RATING SCALE

| RATING | BEHAVIOUR |
|---------------------|---|
| DEFINITELY NEGATIVE | Uncooperative, cries forcefully, extremely negative behaviour |
| NEGATIVE | Reluctant to accept the treatment |
| POSITIVE | Tense cooperation, child is cautious |
| DEFINITELY POSITIVE | Highly cooperative, builds good rapport with the dentist |

Frankl SN. Should the parent remain with the child in the dental operator? J. Dent. Child. 1962;29:150-63.

19

PRE-ANAESTHETIC INVESTIGATIONS

- CBC
- S.electrolyte
- PT-INR
- LFT-RFT
- HIV
- HbSAg
- ANTI-HCV
- CHEST X-RAY
- PAC

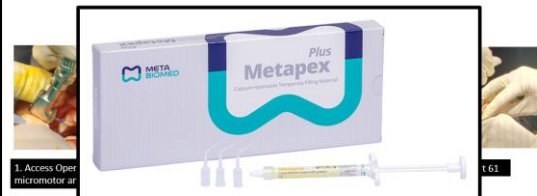The reports were normal and the patient was given the consent to get the treatment under general anaesthesia from all the concerned departments.

20

- Patient was admitted to the Mahatma Gandhi hospital the same day procedures were to be performed considering his age. (NBM instructions were given beforehand)
- Patient was sedated with ketamine (0.3mg/kg) IV, just before taking him into the Operation Theatre
- After taking the patient to the Operation theatre, patient was orally intubated.
- The treatment was initiated, starting with pulpectomy irt 52, 51, 62 which was followed by restoration irt 54 and extraction irt 61

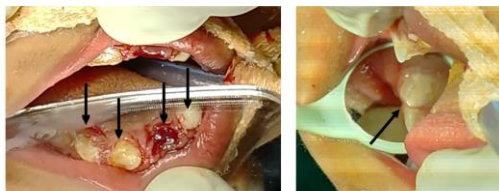
21

INTRA-OPERATIVE PHOTOGRAPHS



22

POST-OPERATIVE PHOTOGRAPHS



1. EXTRACTION irt 61
PULPECTOMY irt 52, 51, 62

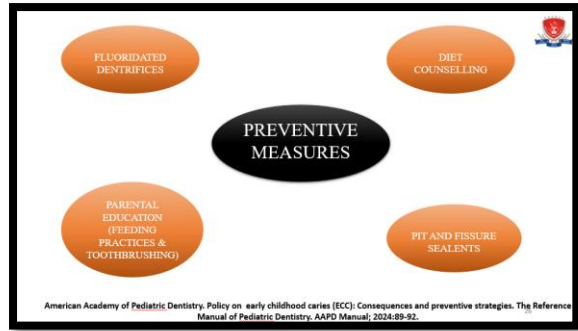
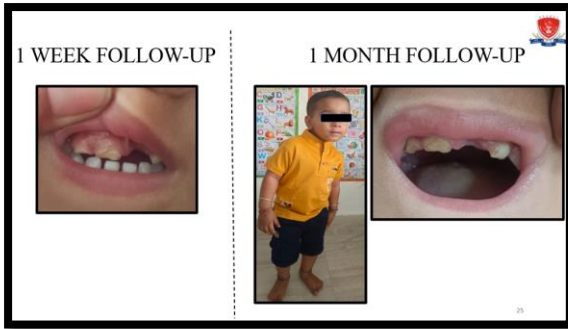2. GIC RESTORATION irt 54

23

- Patient was kept under observation for 1 day
- Patient was then discharged from the hospital without any complications
- Follow-ups were scheduled after 1 week and 1 month.
- After 1 week, there were no signs of swelling and restorations were intact. The tooth socket was healed.
- After 1 month, oral hygiene was improved with no new carious lesions. Parents were satisfied.
- Preventive measures were explained to the parents.

24

Dr. Anant Gopal Nigam
M.D.S., Pedodontics & Preventive Dentistry
Jawahar Education College & Hospital, Jaipur
RSCG - 302005



WHY GENERAL ANAESTHESIA ??

THEORY OF COGNITIVE DEVELOPMENT by Jean Piaget, 1952
He classified the cognitive growth into 4 stages-

1. Sensorimotor period (Birth to 2 years of age) ←
2. Preoperational period (2 to 7 Years of age)

- SIMPLE IDEA OF OBJECTS
- STARTS INTERACTING WITH THE ENVIRONMENT
- ANIMISM
- LIMITED COMMUNICATION
- SIMPLE THOUGHTS

Piaget, Jean. "Piaget's Theory." Piaget and His School (1952): 11-23.

BEHAVIOUR MANAGEMENT

NON-PHARMACOLOGICAL

| | | | |
|--|-----------------|---------------------------|--------------------------|
| PRE APPOINTMENT BEHAVIOUR MODIFICATION | COMMUNICATION | EUPHEMISMS | TELL SHOW DO |
| TENDER LOVE CARE | DESENSITIZATION | MODELING | DISCUSSION |
| PARENTAL PRESENCE OR ABSENCE | VOICE CONTROL | HAND OVER MOUTH TECHNIQUE | PROTECTIVE STABILIZATION |

PRE APPOINTMENT BEHAVIOUR MODIFICATION

EUPHEMISMS


| Dental terminology | Word substitute |
|-----------------------|---------------------------------|
| Air | Wind |
| Impression material | Pudding, mashed potatoes |
| Anesthetic | Sleepy medicine or sleepy water |
| Bur | Brush or pencil |
| Caries | Brown spot: sugar bugs |
| Explorer | Tooth counter |
| Evacuator | Vacuum cleaner |
| Matrix | Fence for filling |
| Rubber dam | Raincoat |
| Stainless steel band | Ring for the tooth |
| Stainless steel crown | Hat for the tooth |
| X-ray | Camera |
| Radiograph | Picture |
| Handpiece | Whistling train |

TELL SHOW DO

TENDER LOVE CARE






Dr. Anant Copal Nigam
FRCR, FRCR, FRCR & Paediatric Dentistry
in Clinical Dental Surgery & Paediatric Dentistry
RSCD - 45485

PARENTAL
PRESENCE OR
ABSENCE



33

PROTECTIVE
STABILIZATION

34

PHARMACOLOGICAL

~~Premedication~~
(Midazolam 0.5mg/kg)
(Oral, IV)

~~Conscious Sedation~~

✓

General Anaesthesia

35

PRIMARY AIM OF PEDODONTICS-
 To provide comprehensive treatment to the child and to instill a positive attitude towards dental experience.

- Preventive measures should be strongly reinforced in these children to prevent recurrence of caries and the need for retreatment under general anesthesia.
- General Anaesthesia is a safe option for uncooperative children. Our institution is equipped with fully functional & dedicated Operation Theaters for pediatric cases to be performed under general anaesthesia. Therefore, we are able to regularly perform treatment under GA.
- After collaborating with the Department of Oral Surgery, Pediatrics and Anaesthesia, we were able to provide successful treatment to the child.

36

TAKE HOME MESSAGE

- The parents should be educated about oral hygiene practices.
- The oral hygiene measures should be started with the eruption of first primary tooth.
- A smear or rice-sized amount of fluoridated toothpaste (approximately 0.1mg fluoride) should be used for children younger than three years of age.
- The first dental visit should be done soon after the first primary tooth erupts/appears in the oral cavity.

(AAPD, 2024)

American Academy of Pediatric Dentistry. Policy on early childhood caries (ECC): Consequences and preventive strategies. The Reference Manual of Pediatric Dentistry. AAPD Manual; 2024:89-92.

37

THANK YOU

38


Dr. Anand Gopal Nigam
 MSc, FRCR, FRCR & Paediatric Dentistry
 & General Paediatric Dentistry, Jodhpur
 RDC - A-2485



Mahatma Gandhi Dental College & Hospital

MAHATMA GANDHI UNIVERSITY OF MEDICAL SCIENCES & TECHNOLOGY, JAIPUR

(Sponsoring Body : India Education Trust)

RIICO Institutional Area, Sitapura, Tonk Road, JAIPUR - 302 022 (Raj.) INDIA

Phone : 0141-2770300, 3292139 • Fax : 0141-2770326

email : principal.dental@mgumst.org

26th DENTAL COMBINED ROUND (DCR)

Topic: " A comprehensive full mouth rehabilitation in a 20 month old child under General anaesthesia"

Presenting Deptt.: Department of Paediatric & Preventive Dentistry

Date: 08/01/2025

Staff Attendance Sheet

| S.NO. | NAME | DESIGNATION | SIGNATURE |
|-------|-----------------------|---|-----------|
| 1. | Dr M L Swarankar | Emeritus Chairperson, MGUMST (Chief Guest) | |
| 2. | Dr Vikas Swarankar | Chairperson cum Chancellor, MGUMST | |
| 3. | Dr Achal Gulati | President cum Vice Chancellor, MGUMST | |
| 4. | Dr V K Kapoor | Pro-Vice Chancellor, MGUMST | |
| 5. | Dr Sudhir Sachdev | Chief Advisor to Chairperson, MGUMST | |
| 6. | Dr Narendra Padiyar U | Principal and Dean, Professor and Head, Dept of Prosthodontics and Crown and Bridge | |
| 7. | Dr Deepak Raisingani | Professor and Head, Dept of Conservative Dentistry and Endodontics | |
| 8. | Dr Sumanth Prasad | Professor and Head, Department of Public Health Dentistry | |
| 9. | Dr Anshuman Jamdade | Professor and Head, Department Oral medicine and Radiology | |
| 10. | Dr Anant Nigam | Professor and Head, Department of Pediatric and Preventive dentistry | |
| 11. | Dr Kamal Bajaj | Professor and Head, Department of Orthodontics and Dentofacial | |

Dr. Anant Nigam
Principal & Head, Pediatric & Preventive Dentistry
Mahatma Gandhi Dental College & Hospital, Jaipur
RSDC - A-5405

| | | | |
|-----|----------------------|---|----------|
| | | Orthopedics | |
| 12. | Dr Ashish Yadav | Professor and Head, Department of periodontology | Ashish |
| 13. | Dr Vikas K. Singh | Professor and Head, Department Oral & maxillofacial surgery | |
| 14. | Dr Manish Jain | Professor and Head, Department of Oral Pathology and Microbiology | |
| 15. | Dr. Shantamu Jain | Prof. Dept of Pediatric & Preventive Dentistry | A.J. |
| 16. | Dr. Meidula Jhekar | Prof. Orthodontics | meidula |
| 17. | Dr. Dileep Soni | prof. Cont. & Endo | Dileep |
| 18. | Dr. Nimedita Saxena | Asst Prof, Pediatric Dentistry | Nimedita |
| 19. | Dr. Aksha | Sen. Lecturer, OMFS | Aksha |
| 20. | Dr. Yashpal Singh | Sen. Lecturer, OMFS | Yashpal |
| 21. | Dr. Guna nappa | Prof. Orthodontics | Guna |
| 22. | Dr. Ranul Maheshwari | As. Lecturer. Orthodontics | Ranul |
| 23. | Dr. Shilpa Seivarden | Op. Reader | Shilpa |
| 24. | | | |
| 25. | | | |
| 26. | | | |
| 27. | | | |
| 28. | | | |
| 29. | | | |
| 30. | | | |
| 31. | | | |
| 32. | | | |
| 33. | | | |
| 34. | | | |

Dr. Anant Gopal Nigam
Prof. & Head, Pediatric & Preventive Dentistry
Mahatma Gandhi Dental College & Hospital, Jaipur
RSDE A-5405



Mahatma Gandhi Dental College & Hospital

MAHATMA GANDHI UNIVERSITY OF MEDICAL SCIENCES & TECHNOLOGY, JAIPUR

(Sponsoring Body : India Education Trust)

RIICO Institutional Area, Sitapura, Tonk Road, JAIPUR - 302 022 (Raj.) INDIA

Phone : 0141-2770300, 3292139 • Fax : 0141-2770325

email : principal.dental@mgumst.org

26th DENTAL COMBINED ROUND (DCR)

Topic: "A comprehensive full mouth rehabilitation in a 20 month old child under General anaesthesia"

Presenting Deptt. Paediatric & Preventive Dentistry

Date: 08/01/2025

Post-Graduate Attendance Sheet

| S.NO. | DEPARTMENT | S.NO. | NAME OF POST-GRADUATE | SIGNATURE |
|-------|--------------------------------|-------|-----------------------|------------------------|
| 1. | Oral Medicine And Radiology | 1 | Kanishka Singh | <i>Kanishka Singh</i> |
| | | 2 | Monika Gupta | <i>Monika Gupta</i> |
| | | 3 | Saurabh Kanawa | |
| | | 4 | Reeya Garg | |
| 2 | Oral And Maxillofacial Surgery | 5 | Aayushi Agarwal | <i>Aayushi Agarwal</i> |
| | | 6 | Krati Jajani | <i>Krati Jajani</i> |
| | | 7 | Mahima Jain | <i>Mahima Jain</i> |
| | | 8 | Chokshi Krupa | <i>Chokshi Krupa</i> |
| | | 9 | Tara Chand | |
| | | 10 | Pooja Sharma | |
| | | 11 | Samiksha Pamnani | |
| | | 12 | Pooja Meena | |
| | | 13 | Divesh Jain | |
| | | 14 | Avni Singh | |
| | | 15 | Hetal Vaya | <i>Hetal Vaya</i> |
| | | 16 | Kshitij Kumawat | |


[Signature]
Anant Gopal Nigam
Paediatric & Preventive Dentistry
Mahatma Gandhi Dental College & Hospital, Jaipur
RSDC - A-5405

| | | | | |
|---|--|----|---------------------------------|-----------------------|
| | | 17 | Sanjeevani | <i>Sanjani</i> |
| | | 18 | Shalu Choudhary | <i>Shalu</i> |
| | | 19 | Swati Verma | |
| 3 | Prosthodontics And Crown & Bridge | 20 | Rajbir Kaur | <i>Rajbir Kaur</i> |
| | | 21 | Naman Goyal | |
| | | 22 | Poonjee Gupta | |
| | | 23 | Ayushi Goyal | |
| | | 24 | Khandhedia Harsh Jayeshkumar | |
| | | 25 | Rishika Singh | |
| | | 26 | Sanya Dayma | |
| | | 27 | Patil Shweta Narendra Kumar | |
| | | 28 | Khushboo Meena | |
| | | 29 | Sheetal Vijay | |
| | | 30 | Akanksha Verma | <i>Akanksha Verma</i> |
| | | 31 | Muskan Malik | <i>Muskan</i> |
| | | 32 | Nandini Sharma | <i>Nandini</i> |
| | | 33 | Prachi Singh | <i>Prachi Singh</i> |
| | | 34 | Shruti Ashok Rathod | <i>Shruti</i> |
| 4 | Conservative Dentistry & Endodontics | 35 | Sohan Sharma L | <i>Sohan</i> |
| | | 36 | Chanchal Meena | <i>Chanchal</i> |
| | | 37 | Ruchi Chandak | <i>Ruchi</i> |
| | | 38 | Poorva Sharma | |
| | | 39 | Anshum Jain | <i>Anshum</i> |
| | | 40 | Kusum Meena | <i>Kusum M</i> |
| | | 41 | Praveen Singh Chauhan | |
| | | 42 | Sakshi Bilaiya | |
| | | 43 | Vookanti Venkat Ramana Reddy | <i>Vunkanti</i> |
| | | 44 | Mohit Kumar Jyotiyana | |
| | | 45 | Anusha Saxena | <i>Saxena</i> |
| | | 46 | Khushi Bhargava | |

Dr. Anant Gopal Nigam
F.M.S. & Head, Pediatric & Preventive Dentistry
Jawahar Education Trust College & Hospital, Jaipur
R500 - A 5405

| | | | | |
|---|---|----|---------------------------------------|------------|
| | | 47 | Kiran Gurdasani | Kiran |
| | | 48 | Saumya Kanode | Saumya |
| | | 49 | Mutyalarwar Sunaina Shanka Shankar | Sunaina |
| 5 | Paediatrics & Preventive Dentistry | 50 | Vipul Sharma | Vipul |
| | | 51 | Simran Vangani | Simran |
| | | 52 | Vritika Singh | Vritika |
| | | 53 | Ghawate Nikhil Dattatraya | Nikhil |
| | | 54 | Mrunal Milind Bandiwar | Mrunal |
| | | 55 | Harsha Patni | Harsha |
| | | 56 | Riya Bafna | Riya |
| | | 57 | Surbhi Surana | Surbhi |
| | | 58 | Anugya Jain | Anugya |
| | | 59 | Muskan Rathore | Muskan |
| | | 60 | Sanjana Verma | |
| | | 61 | Sanika Pravin Rathi | Sanika |
| | | 62 | Khushboo Parihar | Khushboo |
| | | 63 | Sanchi Pramod Meshram | |
| | | 64 | Aditi Choudhary | Aditi |
| 6 | Periodontology | 65 | Hemant Sharma | |
| | | 66 | Shashidhar Ojha | Shashidhar |
| | | 67 | Vaishali Sharma | |
| | | 68 | Pooja Shukla | |
| | | 69 | Srashti Katiyar | |
| | | 70 | Priyanka Pawar | Priyanka |
| | | 71 | Aakanksha | Aakanksha |
| | | 72 | Abhivyakti Rajput | Abhivyakti |
| | | 73 | Keertika Rathore | Keertika |
| 7 | Orthodontics & Dentofacial Orthopaedics | 74 | Priyanka Agarwal | Priyanka |
| | | 75 | Mausham Chaudhary | Mausham |
| | | 76 | Harshita Gautam | Harshita |
| | | 77 | Soni Hitesh Kumar | Hitesh |

| | | |
|----|-------------------|---------------------|
| 78 | Pallavi Goswami | <u>Pallavi</u> |
| 79 | Modak Ankur Rahul | <u>Modak</u> |
| 80 | Heena Khan | |
| 81 | Richa Sharma | <u>Richa</u> |
| 82 | Mantrishna Sarma | |
| 83 | Nivita Jewaria | |
| 84 | Adarsh | <u>Adarsh</u> |
| 85 | Divyansh Raghav | <u>Divyansh</u> |
| 86 | Pooja Sharma | <u>Pooja Sharma</u> |
| 87 | Rashmi Upadhyay | <u>Rashmi</u> |
| 88 | Sanya Mathur | <u>Sanya Mathur</u> |


Dr. Azant Gopal Nigam
 Prof. & Head, Podiatric & Preventive Dentistry
 Mahalma College & Hospital, Jaipur
 RSDC - A-5405



Mahatma Gandhi Dental College & Hospital

(A UNIT OF MAHATMA GANDHI UNIVERSITY OF MEDICAL SCIENCES & TECHNOLOGY)

RIICO Institutional Area, Sitapura, Tonk Road, JAIPUR - 302 022 (Raj.) INDIA



DENTAL COMBINED ROUNDS (DCR)

CERTIFICATE OF APPRECIATION

This is presented to Dr. Anugya Jain of Department of
Pediatrics & Preventive Dentistry
for making a Presentation in Dental Combined Rounds

on 08.01.2025


Dr. Anshuman Jamdade

Professor & Head

Dept. of Oral Medicine & Radiology
Convenor, Dental Combined Rounds.


Dr. Narendra Padiyar U

Principal & Dean
MGDCH, Jaipur


Dr. V. K. Kapoor

Pro-Vice Chancellor
MGUMST


Dr. Anant Gopal Nigam
Head, Pediatric & Preventive Dentistry
Mahatma Gandhi Dental College & Hospital, Jaipur
RSDC - A-5405



Mahatma Gandhi Dental College & Hospital

(A UNIT OF MAHATMA GANDHI UNIVERSITY OF MEDICAL SCIENCES & TECHNOLOGY)




RIICO Institutional Area, Sitapura, Tonk Road, JAIPUR - 302 022 (Raj.) INDIA

DENTAL COMBINED ROUNDS (DCR)

CERTIFICATE OF APPRECIATION


This is presented to Dr. Nikhil Ghawate of Department of
Pediatrics & Preventive Dentistry
for making a Presentation in Dental Combined Rounds

on 08.01.2025


Dr. Anshuman Jamdade


Professor & Head

Dept. of Oral Medicine & Radiology
Convenor, Dental Combined Rounds.


Dr. Narendra Padiyar U


Principal & Dean

MGDCH, Jaipur


Dr. V. K. Kapoor

Pro-Vice Chancellor

MGUMST


Dr. Anant Gopal Nigam
Head, Pediatric & Preventive Dentistry
Mahatma Gandhi Dental College & Hospital, Jaipur
RSDC - A-5405